

## Effect of dehydroepiandrosterone on ovarian morphology and follicular apoptosis following 4-vinylcyclohexene diepoxide induced premature follicle loss in rats

Dehydroepiandrosterone and premature ovarian loss in a rat model

Mehmet Caner Özer<sup>1</sup>, Mehmet Kaya<sup>2</sup>, Ahmet Berkiz Turp<sup>3</sup>, Cengiz Bal<sup>4</sup>, Nilüfer Erkasap<sup>5</sup>, Didem Turgut Coşan<sup>6</sup>, Hikmet Hassa<sup>7</sup>

<sup>1</sup>Department of Infertility Center, Denizli State Hospital, Denizli,

<sup>2</sup>Department of Obstetrics and Gynecology, Mersin State Hospital, Mersin,

<sup>3</sup>Department of Obstetrics and Gynecology, Harran University Medical Faculty, Şanlıurfa,

<sup>4</sup>Department of Biostatistics, Eskisehir Osmangazi University Medical Faculty, Eskisehir,

<sup>5</sup>Department of Physiology, Eskisehir Osmangazi University Medical Faculty, Eskisehir,

<sup>6</sup>Department of Medical Biology, Eskisehir Osmangazi University Medical Faculty, Eskisehir,

<sup>7</sup>Department of Obstetrics and Gynecology, Eskisehir Osmangazi University Medical Faculty, Eskisehir, Turkey

### Abstract

**Aim:** Chemical-induced depletion of ovarian follicle pool can lead to premature ovarian failure in rats. In the rat model of 4-vinylcyclohexene diepoxide (VCD)-induced ovarian follicular loss, we tested the hypothesis that Dehydroepiandrosterone (DHEA) could be reversed by short and long-term treatment of follicular loss. **Material and Method:** All rats were divided into groups for study and treated with dimethylsulfoxide (DMSO) (control group), VCD alone, DHEA and VCD + DHEA for only 15 days. At the end of 15 days, some of the rats were killed as a group of 15 days. Others continued their treatment with DHEA to form groups of 35 and 55 days, respectively. For each animal, follicle numbers were counted and photographed. **Results:** VCD treatment produced a sustainable state of ovotoxicity throughout the experiment, diminishing the numbers of both primordial and primary follicles ( $p < 0.05$ ). Only VCD-treated rats showed apoptotic cells at very high rates with TUNEL and caspase-3 immunohistochemical staining ( $p < 0.05$ ). On 15th day, concurrent use of DHEA increases the percentages of both normal primordial and primary follicles. More cystic follicles were observed in both VCD- and DHEA-treated rats, compared to controls ( $p < 0.05$ ). **Discussion:** In this ovotoxicity model with VCD in rats, administration of DHEA provides protection in the number of primordial follicles in the short and long term.

### Keywords

Premature Ovarian Failure; 4-Vinylcyclohexene Diepoxide; Dehydroepiandrosterone; Apoptosis; Rats

DOI: 10.4328/ACAM.6163 Received: 13.01.2019 Accepted: 13.02.2019 Published Online: 19.02.2019 Printed: 01.03.2020 Ann Clin Anal Med 2020;11(2):104-110

Corresponding Author: Mehmet Caner Özer, Department of Infertility Center, Denizli State Hospital, Denizli, Turkey.

GSM: +905052990855 E-Mail: mc.ozet77@gmail.com.

ORCID ID: <https://orcid.org/0000-0002-4398-9598>

## Introduction

Dehydroepiandrosterone sulphate (DHEA) is an endogenous steroid originating from zona reticularis of the adrenal cortex and human ovarian theca cells [1]. It is an essential hormone for ovarian folliculogenesis [1,2]. Several studies in the literature have addressed the potential ameliorating role of DHEA supplementation on ovulation, pregnancy and even the miscarriage rates among women with premature ovarian failure or diminished ovarian reserve in IVF cycles [2-6].

DHEA supplementation has been found to increase ovarian response, reduce cancellation cycles and increase the embryo quality in poor responder IVF cases [7,8]. Proposed mechanisms for DHEA action have been documented as either acting as a promoting factor for gonadotropin effect by increasing insulin-like growth factors (IGF-1) or by decreasing the atretic follicles, as well as the formation of the polycystic environment in the ovaries [9,10]. In addition, it has been reported that there is a synergistic effect between DHEA and gonadotropins or positive effects on follicle recruitment [3,11].

On the other hand, chemical-induced depletion of ovarian follicle pool can also lead to premature ovarian failure in rats and has been proved by several studies using 4-vinylcyclohexene diepoxide (VCD), an occupational chemical used as an industrial diluent for epoxides [12-15]. Collectively, morphological and biochemical findings suggest that VCD results in a follicle loss by accelerating the normal process of atresia in small preantral follicles via apoptosis [13-15].

DHEA induced apoptosis in hippocampal neurons after increased caspase 3 activity and poly (ADP (adenosine diphosphate) ribose) polymerase activity in the absence of trophic factors, and decreased apoptosis induced by DHEA after IGF-1 administration [16]. It has been shown that DHEA (S) protects rat hippocampal neurons against NMDA-induced excitotoxicity and Allopregnelone reduces NMDA-induced excitotoxicity in human neurons, DHEA(S) protects allopregnelone's chromophore cells and sympathoadrenal PC12 cells against apoptosis in a dose- and time-proportional manner [17]. VCD may be thought to be beneficial against apoptosis in response to increased apoptosis in the overlying micro-environment.

The aim of this experimental study is to investigate the effect of DHEA 15, 35, and 55 days of treatment on ovarian follicles following the 15 days of VCD administration and to determine whether VCD-induced ovotoxicity in rat model can be reversed by prolonging DHEA treatment.

## Material and Methods

### Animals

Immature female Sprague-Dawley rats (28 days old), weighing 40 to 60 gr, were obtained and housed in plastic cages (4 to 6 animals per cage). They were maintained on 12-h light/dark cycles in a well-ventilated room at a controlled temperature of  $22 \pm 2^\circ\text{C}$ . The animals were allowed to acclimate to animal facilities for one week before the initiation of experiments. Rats were provided with food (Purina rat chow, St Louis, MO) and water ad libitum. All the experiments were approved by the Eskisehir Osmangazi University Institutional Animal Care Ethical Committee (TICAM; 02.01.2008/29) and conformed to the Guide for the Care and Use of Experimental Animals.

### Treatment

A total number of 120 rats were allocated to this study. Rats were initially treated daily for 15 days with dimethyl sulfoxide (n:10,

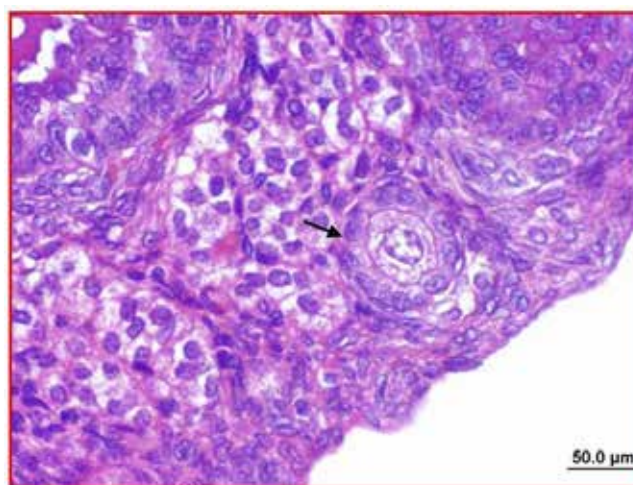
DMSO, ip; Sigma Chemical CO. St Louis MO, USA, 48H0074,11) as vehicle control group; VCD alone (n:10, 160mg/kg/d, ip; Fluka, 1302946, 250 ml, dissolved in 1.1 mixture of DMSO, VCD group) alone and concurrently with DHEA (n:10; Sigma, D4000, 25 g; ip, 6mg/100g body weight/ 0.2 ml DMSO, VCD+DHEA group) and DHEA alone (n:10; Sigma, D4000, 25 g; ip, 6mg/100g body weight/ 0.2 ml DMSO, DHEA group), respectively. After 15 days of dosing, rats were either sacrificed or treatment with DHEA was prolonged to complete total treatment days of 35 (n:40) and 55 days (n:40), respectively.

Estrous cycles of each animal were monitored daily at 08.00 by vagina cytology from the date of vaginal opening to in all rat groups. Rats were sacrificed under the combination of 90 mg/kg ketamine (Ketalar flacon®, 50mg/ml, Pfizer Turkey) and 10mg/kg Xylazine ( Rompun DS® 2% injectable solution, Bayer, Turkey) anesthesia. Sacrifications of animals was performed on the evening of days 15, 35, and 55, based on the treatment arms.

### Histologic evaluation of follicle numbers

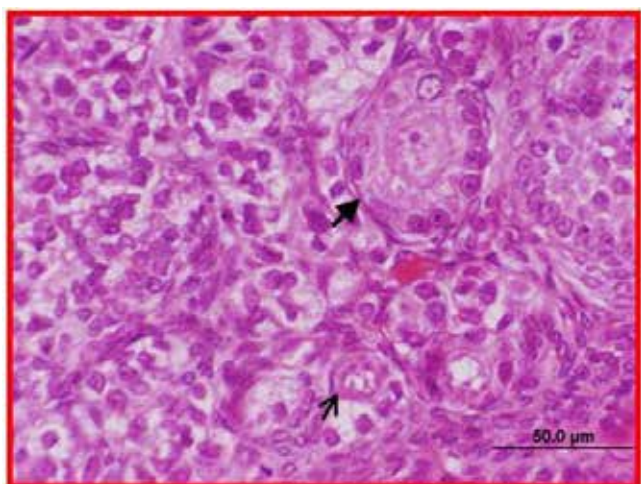
Ovaries were trimmed free of fat and placed in Bouin fixative (2h), dehydrated with serials of ethanol, cleared in xylene, and embedded in paraffin paraffin-embedded and serially sectioned (4-5µm) mounted and stained with hematoxylin and eosin.

Follicles were counted in every 40th section (10-13 sections per ovary) to avoid double counting of small preantral follicles (25-100µm in diameter). Unhealthy follicles were distinguished from healthy follicles by their granulosa cell content pyknotic bodies and intense eosinophilic staining of oocytes, as shown in Figure 1 and 2. Based on the procedure of Flaws et al. [19] and briefly summarized as follows: follicles were classified as primordial (oocyte surrounded by a single layer of flattened cuboidal cells), primary (enlarged oocyte surrounded by a single layer of <20 cuboidal cells with no oocyte growth), secondary (oocyte surrounded by multiple layers of granulosa cells), antral (follicles containing a fluid-filled antrum) and atretic follicles (presence of pyknosis and chromatin dispersion and eosinophilic stained oocytes). Sections obtained through the center of the follicles (largest cross-section) were chosen for the immunohistochemistry. Histologic images were captured with an Olympus DP 70 inverted microscope (Olympus Corp, Tokyo, Japan). The final magnification was 40X.



**Figure 1.** Normal primary follicle is observed. H&E, Scalebar: 50 µm. Magnification x 40.



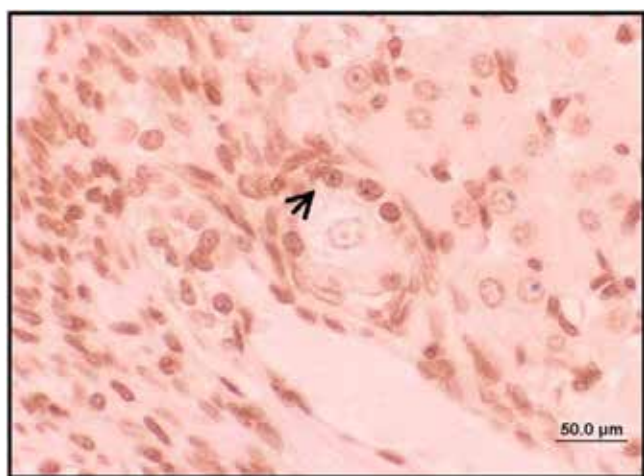


**Figure 2.** Ovarian tissue section in VCD group. Degenerated (arrow) primordial follicle, granulosa cells with irregular borders and primary follicle containing degenerated oocyte are observed (arrowhead). H&E, Scalebar: 50μm. X 40 Magnification.

**Immunohistochemical evaluation**

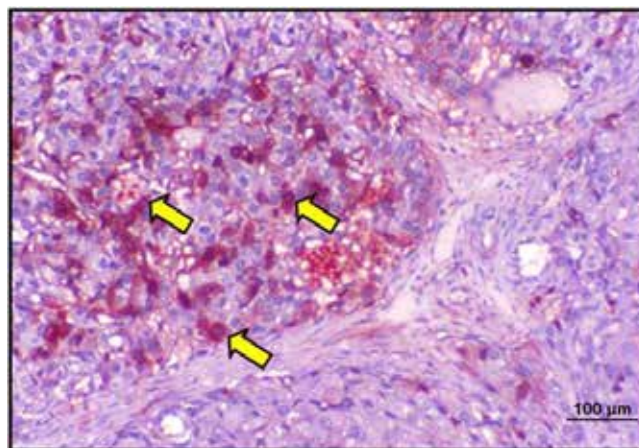
For all immunostaining procedures, tissues embedded in paraffin were cut in 5μm-thick sections, then deparaffinized in xylene and rehydrated through a graded ethanol series in distilled water. Endogenous peroxidase activity was blocked by immersing the sections in 3% hydrogen peroxide in methanol for 30 min at room temperature.

DNA fragmentation characteristic of apoptosis was detected with TUNEL (TdT-mediated biotin nick end-labeling) test, and by using and Apoptag Plus Peroxidase In Situ Apoptosis Detection Kit (S7101, Chemicon International, USA). After intense washing with distilled water, the sections were then soaked in TdT buffer for 15 min and then incubated with TdT buffer containing biotin for 60 min at room temperature. The biotinylated dUTP molecules incorporated into the nuclear DNA were reacted with HRP-conjugated streptavidin (1:100 dilution) for 30 min at room temperature, after which the peroxidase coloring reaction was performed by immersing section into Tris-HCL buffer (pH 7.6) containing 0.3mg/ml DAB, 10nmol/l imidazole and 0.003% $H_2O_2$ . The sections were counterstained with hematoxylin and eosin. Negative controls were reacted in parallel with the omission of the terminal transferase. The evaluation was carried out by counting dark brown cells stained at ×40 magnification in randomly selected sections of each over-tissue with light microscopy (Figure 3).

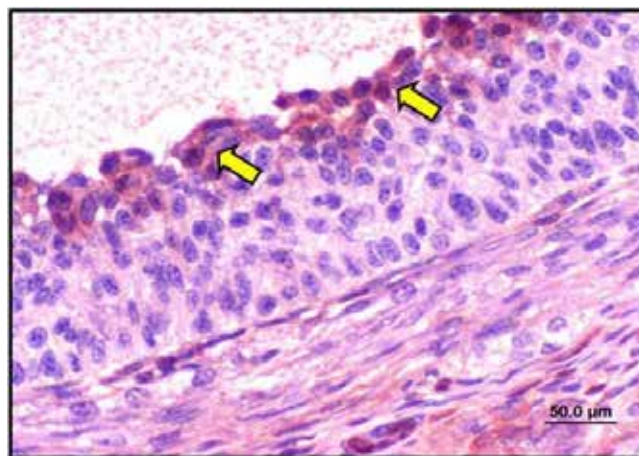


**Figure 3.** Ovarian tissue section in VCD group. Few numbers of TUNEL positive apoptotic cells (arrow) within granulosa cells of normal primary follicle. Scalebar:50μm

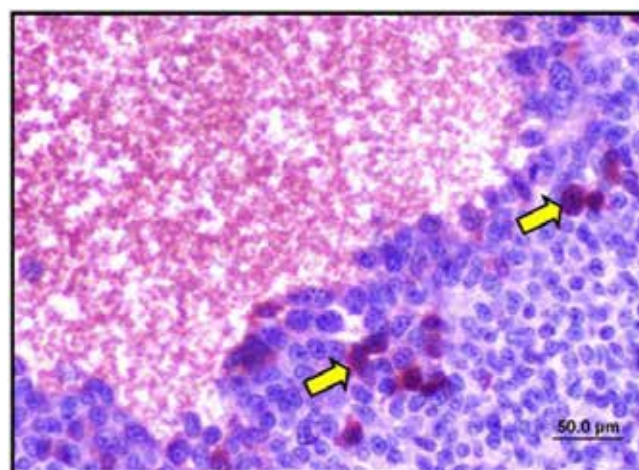
Caspase-3 immunostaining was performed on tissue sections by using Rabbit Anti-Active Caspase-3 Polyclonal Antibody (AB3623 Chemicon International, USA) as a primary antibody and HRP/AEC (Thermo Fisher Scientific Anatomical Pathology, USA) as a secondary antibody. The intensity of caspase-3 immunostaining was scored by two experienced investigators semiquantitatively on a scale of 0 to 3 as follows: 0- no staining (in follicle developmental stages, in certain oocytes, granulosa, or somatic cells); 1- mild staining; 2- intense staining (Figures 4, 5 and 6). The investigators were blind to the samples of the study groups.



**Figure 4.** Ovarian tissue section in VCD group. Highly intense caspase-3 positive cells (arrows) in the stroma. CASPASE 3, Scalebar: 50μm



**Figure 5.** Ovarian tissue section in VCD group. Granulosa cells adjacent to the antral cavity show highly intense (arrows) caspase-3 positivity. CASPASE 3, Scalebar: 50μm



**Figure 6.** Ovarian tissue section in the DHEA group. Granulosa cells of antral follicle show mildly-stained (arrows) caspase-3 positive cells. CASPASE 3, Scalebar: 50μm

### Statistical analysis

Statistical analyses were performed using SPSS for Windows version 15.0 (SPSS, Chicago, IL, USA). Data are presented as mean  $\pm$  SE or median  $\pm$  (min, max values) depending on the distribution of variables. The effect of treatments on follicle number (percent normal) and follicle damage (percent atretic) was determined by one-way analysis of variance (ANOVA) with posthoc Tukey test and by the Mann-Whitney U test when necessary. Analyses of TUNEL and caspase-3 immunohistochemical stainings on follicles or ovarian stroma were performed by using the Kruskal-Wallis analysis and the Pearson's Chi-Square tests, respectively. Significance was assigned at  $p < 0.05$ .

### Results

Menstrual cyclicity, based on vaginal cytology was not abolished in all rat groups during 55 days of the experiment. After 15 days of daily dosing with VCD alone, DHEA, VCD+DHEA, and finally DMSO as a vehicle substance, percentages of follicles in the ovarian tissue sections were shown in Table 1. Based on follicle counting, in the present study, 15 days of VCD treatment alone resulted in a significant loss of normal primordial and primary follicles together with increased atretic follicles, compared to other groups ( $p < 0.001$ ). Additionally, DHEA group has less atretic primordial and primary follicles, compared to DHEA +VCD group, as shown in Table 1. Using DHEA concurrently with VCD increased the percentages of both primordial and primary follicles ( $p < 0.05$ ).

The same scenario was also evident on the 35th day of the experiment. More primordial and primary follicles became atretic in VCD-treated group, compared to other groups, as shown in Table 2. Interestingly, DHEA following VCD use appeared to increase the percentage of normal primordial follicles ( $p < 0.001$  compared to VCD group). While, DHEA treatment alone (DHEA group) resulted in a reduced percentage of primary follicles, compared to controls ( $p < 0.05$ ). The same observation is also evident for the findings on 55th day is shown in Table 3, with no effect on primordial follicles.

On the 55th day of the experiment, VCD arms showed similar patterns of results with much higher percentages of atretic follicles and less normal primordial and primary follicles compared to other groups, as shown in Table 3. In addition, VCD+DHEA group had a decrease in the percentage of atretic primordial follicles and a remarkable increases in primordial follicle percentage ( $p < 0.001$  compared to VCD group). However, it did not restore the primordial follicle numbers to control levels. On 35th and 55th days of the experiment, prolonging the use of DHEA following the first 15 days of VCD use did not result in an increase in the percentages of primary follicles.

Table 4 shows the distributions of TUNEL positivity among all types of follicles on 15th day of the experiment. As clearly shown in Table 4, both VCD and VCD+DHEA group had a significant TUNEL positive follicles, compared to controls ( $p < 0.01$ ). On 35th day of the experiment, a higher number of TUNEL positive cells were observed, compared to controls, as shown in Table 5. TUNEL positive cells were also evident in secondary follicles of VCD group. On 55th day of the experiment, apoptotic process is only observed in primary follicles of VCD group, compared to controls ( $p = 0.009$ ) and VCD+DHEA group ( $p = 0.01$ ), respectively, as shown in Table 6.

As determined by caspase-3 immunohistochemical staining, there were no apparent differences in the degree of caspase-3 immunostaining of primordial and primary follicles among four

groups ( $p > 0.05$  in all comparisons, Pearson's  $\chi^2$  test). Conversely, on all three planned days of the experiments, VCD group had the highest degree of staining compared to other groups, as shown in Figure 7, 8, and 9, respectively ( $p < 0.05$  in all comparisons, Pearson's  $\chi^2$  test).

**Table 1.** Percentages of normal and atretic primordial and primary follicles on day 15 of the experiment in vehicle controls; VCD-induced\*; DHEA-treated, and finally VCD\*+DHEA treated rats. Ten rats were allocated for each group.

Follicles (%)	Controls	VCD group	DHEA group	VCD+DHEA group
Normal primordial	13.3 $\pm$ 11.3 <sup>a,β,γ</sup>	91.8 $\pm$ 11.4 <sup>μ</sup>	70.0 $\pm$ 18.4	90.1 $\pm$ 4.7
Atretic primordial	9.9 $\pm$ 4.7	86.6 $\pm$ 11.3 <sup>a,β,γ</sup>	8.1 $\pm$ 1.1	30.0 $\pm$ 18.2
Normal primary	84.1 $\pm$ 7.4	35.4 $\pm$ 12.7 <sup>a,β,γ</sup>	87.5 $\pm$ 13.6	88.6 $\pm$ 17.5
Atretic primary	15.8 $\pm$ 7.48	64.5 $\pm$ 12.7 <sup>a,β,γ</sup>	12.5 $\pm$ 13.6	11.3 $\pm$ 17.5

\* VCD and vehicle controls were given only for fifteen days.

α: versus control group ( $p < 0.001$ ), β: versus DHEA group ( $p < 0.001$ ), γ: versus VCD+DHEA group; μ: versus VCD+DHEA group  $p < 0.001$ .

**Table 2.** Percentages of normal and atretic primordial and primary follicles on day 35 of the experiment in vehicle controls; VCD-induced\*; DHEA-treated and VCD\*+DHEA-treated rats. Ten rats were allocated for each group.

Follicles (%)	Controls	VCD group	DHEA group	VCD+DHEA group
Normal primordial	87.4 $\pm$ 6.4	6.6 $\pm$ 1.4 <sup>a,β,γ</sup>	80.6 $\pm$ 10.7	48.2 $\pm$ 15.2 <sup>δ,ψ</sup>
Atretic primordial	12.5 $\pm$ 6.4	93.3 $\pm$ 14.0 <sup>a,β,γ</sup>	19.3 $\pm$ 10.7	51.7 $\pm$ 15.2 <sup>δ,ψ</sup>
Normal primary	85.8 $\pm$ 6.6	19.2 $\pm$ 14.8 <sup>α,β</sup>	65.9 $\pm$ 17.3 <sup>ω,π</sup>	37.0 $\pm$ 18.2 <sup>δ,ψ</sup>
Atretic primary	14.1 $\pm$ 6.6	80.7 $\pm$ 14.8 <sup>α,β</sup>	34.0 $\pm$ 17.3 <sup>ω,π</sup>	62.9 $\pm$ 18.2 <sup>δ,ψ</sup>

\* VCD and vehicle controls were given only for fifteen days.

α: versus control group ( $p < 0.001$ ), β: versus DHEA group ( $p < 0.001$ ), γ: versus VCD+DHEA group, ( $p = 0.01$ ); ω: versus VCD+DHEA group ( $p < 0.001$ ), π: versus control group ( $p = 0.03$ ), δ: versus DHEA group ( $p < 0.001$ ), ψ: versus control ( $p < 0.001$ )

**Table 3.** Percentages of normal and atretic primordial and primary follicles on day 55 of the experiment in vehicle controls; VCD-induced\*; DHEA-treated and VCD\*+DHEA-treated rats. Ten rats were allocated for each group.

Follicles (%)	Controls	VCD group	DHEA group	VCD+DHEA group
Normal primordial	87.4 $\pm$ 6.4	6.6 $\pm$ 1.34 <sup>a,β,γ</sup>	86.4 $\pm$ 7.6	39.2 $\pm$ 19.6 <sup>δ,ψ</sup>
Atretic primordial	12.5 $\pm$ 6.4	87.5 $\pm$ 23.1 <sup>a,β,γ</sup>	13.5 $\pm$ 7.6	60.7 $\pm$ 19.6 <sup>δ,ψ</sup>
Normal primary	85.8 $\pm$ 6.6	20.8 $\pm$ 15.1 <sup>α,β</sup>	65.2 $\pm$ 5.4 <sup>ω,π</sup>	33.8 $\pm$ 17.4 <sup>ψ</sup>
Atretic primary	14.1 $\pm$ 6.6	79.1 $\pm$ 15.1 <sup>α,ε</sup>	34.7 $\pm$ 5.4 <sup>ω,π</sup>	66.2 $\pm$ 17.4 <sup>ψ</sup>

\* VCD and vehicle controls were given only for fifteen days.

α: versus control group ( $p < 0.001$ ), β: versus DHEA group ( $p < 0.001$ ), γ: versus VCD+DHEA group; δ: versus DHEA group ( $p < 0.001$ ), ψ: versus control ( $p < 0.001$ ), ω: versus VCD+DHEA group ( $p < 0.001$ ), π: versus control group ( $p < 0.001$ ), ζ: versus DHEA group ( $p = 0.01$ )

**Tables 4.** Number of TUNEL(+) follicles on day 15 of the experiment in vehicle controls; VCD-induced\*; DHEA-treated and VCD\*+DHEA-treated rats. Data are expressed as median $\pm$ (min, max values). Ten rats were allocated for each group.

Follicles	Vehicle controls	VCD group	DHEA group	VCD+DHEA group
Primordial	0 (0;0)	8 (0;15)	0 (0;2)	0 (0;5)
Primary	0 (0;0)	15 (0;30) <sup>α</sup>	3 (0;16)	10 (0;12) <sup>β</sup>
Secondary	4 (3;46)	15 (8;55)	20 (7;5;24)	17 (3;32)
Antral	35(16;83)	64(46;155)	50(29;410)	50(0;119)

\* VCD and vehicle controls were given only for fifteen days.

α: versus control group ( $p < 0.01$ ), β: versus control group ( $p < 0.01$ ).



**Tables 5.** Number of TUNEL(+) follicles on day 35 of the experiment in vehicle controls; VCD-induced\*; DHEA-treated and VCD\*+DHEA-treated rats. Data are expressed as median±(min, max values). Ten rats were allocated for each group.

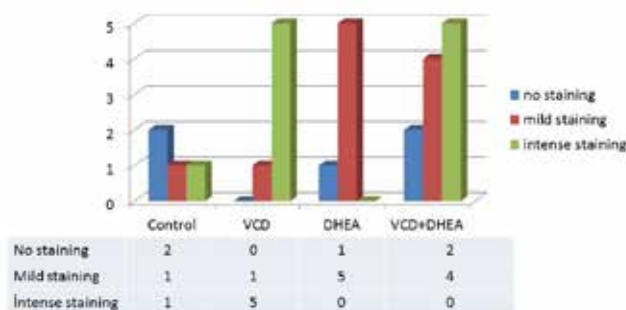
Follicles	Vehicle controls	VCD group	DHEA group	VCD+DHEA group
Primordial	0 (0;1)	10 (0;20) <sup>a,b,g</sup>	0 (0;2)	0 (0;2)
Primary	1 (0;3)	13 (6;37) <sup>d,w,y</sup>	2.5 (0;10)	1 (0;4)
Secondary	8 (3;24)	44.5 (14;250) <sup>s</sup>	22.5 (0;64)	12 (4;175)
Antral	36 (16; 90)	91 (0;210)	60,5 (0;550)	7 (0;85)

\* VCD and vehicle controls were given only for fifteen days  
a: versus control group (p=0.02), b: versus DHEA group (p=0.01), g: versus VCD+DHEA group (p=0.02), d: versus control group (p<0.001), w: versus DHEA group (p=0.005), y: versus VCD+DHEA group (p<0.001), s: versus control group (p<0.004).

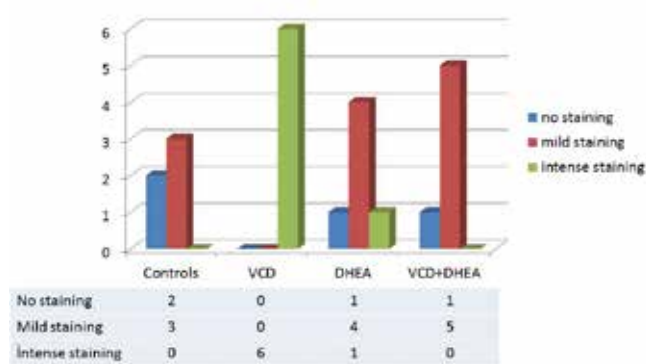
**Tables 6.** Number of TUNEL(+) follicles on day 55 of the experiment in vehicle controls; VCD-induced\*; DHEA-treated and VCD\*+DHEA-treated rats. Data are expressed as median±(min, max values). Ten rats were allocated for each group.

Follicles	Vehicle controls	VCD group	DHEA group	VCD+DHEA group
Primordial	0 (0;2)	0 (0;10)	0 (0;0)	0 (0;3)
Primary	0 (0;5)	12 (2;25) <sup>a,b</sup>	6 (0;10)	2 (0;6)
Secondary	14,5 (2;35)	0 (0;54)	12,5 (2;27)	19 (10;64)
Antral	38 (5; 118)	25 (0;94)	54 (28;152)	20.5 (0;76)

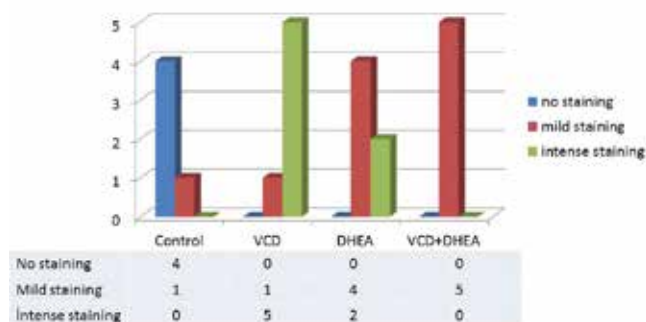
\* VCD and vehicle controls were given only for fifteen days  
a: versus control group (p=0.009), b: versus VCD+DHEA group (p=0.01).



**Figure 7.** The intensity of caspase-3 immunohistochemical staining of ovarian stroma among four groups on day 15 of the experiment (Pearson's  $\chi^2$ :24.84, DF:6, p=0.008)



**Figure 8.** The intensity of caspase-3 immunohistochemical staining of ovarian stroma among four groups on day 35 of the experiment (Pearson's  $\chi^2$ :20.37, DF:6, p=0.001)



**Figure 9.** The intensity of caspase-3 immunohistochemical staining of ovarian stroma among four groups on day 55 of the experiment (Pearson's  $\chi^2$ :26.85, DF:6, p=0.001) (c).

**Discussion**

The present study has definitely established a rat ovotoxic effect of VCD following 15 days of the treatment. This finding is in agreement with previous studies that have shown that repeated treatment of rats with VCD selectively destroys small preantral (primordial and primary) follicles by accelerating apoptotic events associated with the normal process of atresia [13-15, 18-20]. Following the cessation of VCD dosing, relative to controls, lower percentages of normal primordial, primary follicles were observed in long term, as shown in Tables 1, 2, and 3 respectively. During this period, all treated rats did not exhibit any persistent diestrus state. Mayer et al. [18 ] have shown that 15 days of VCD treatment on rats resulted in a follicular loss by 30th day and an evident disruption in the cyclicity by day 360 following the onset of VCD dosing. Hence, VCD-induced follicular disruption follows a sequence of events with the loss of follicles firstly, followed by loss of cyclicity.

The primordial follicle is the most immature stage of development, largely after birth [21]. As the pool of primordial follicles is depleted, there is a subsequent reduction in the numbers of developing follicles to the point where they can't be regenerated. Hence, the stage of follicular development disrupted by exposure to environmental and occupational chemicals like VCD determines the detrimental effect on the future reproduction function. DHEA treatment following a concurrent use with VCD for 15 days, resulted in remarkably high percentages of both primordial and primary follicles, is shown in Table 1. As has been explained, following 15 days of VCD dosing DHEA, DHEA treatment was continued. On 35th and 55th days of the experiment, animals were again sacrificed and ovarian morphology was assessed. Interestingly, only the percentage of normal primordial follicles was increased, compared to VCD-treated group. Hence, these findings provide support that concurrent use of DHEA has a long-term protective effect against VCD-induced ovotoxicity on primordial follicles. Which mechanisms are involved in this increment of primordial follicles remains to be elucidated. This observation led us to think of two possible explanations: either the primordial follicles escaped from the VCD-induced ovotoxicity via apoptotic signal reduction or some new follicles were formed to overcome VCD-induced follicle depletion. Bukovsky et al. [22 ] addressed the follicular renewal in adult human and rat ovaries, emphasizing the ovarian surface epithelium (OSE)-derived stem cells. Most probably, diminished apoptotic signaling together with OSE-derived stem cell activation may play a role in mediating the effect of DHEA on primordial follicle pool. However, this possible association requires further evaluation. Elbetagy et al. [23] treatment of granulosa cells with low dose

DHEAS increased the expression of androgen receptor, aromatase, 3-beta-hydroxysteroid dehydrogenase, and cyclooxygenase-2, reduced the expression of estrogen receptor beta, and increased estrone and estradiol levels. To sum up, DHEA not only has a beneficial effect on the percentages of primordial follicles but also affects the steroidogenesis. Another important remark is the fact that the percentage of normal primary follicles was decreased and atretic primary follicles were decreased in DHEA arms, as shown in Table 2, 3. Hence, a long-term supplement of DHEA alone has a negative impact on folliculogenesis.

Hassa et al. [11] performed an increase in primordial, primer and growing follicles when DHEA was administered to rats subjected to VCD. In this study, DHEA decreased in the rate of atresia in the given group. It is thought that it may be connected to the change in the microenvironment rubbing together with unexplained reason.

Furthermore, DHEA effect on primordial follicles was observed to be mediated via reduction of apoptosis. On the 35th day of the experiment, apoptotic cell count assessed via TUNEL was decreased in both primordial and primary follicles as shown in Table 5; whereas on the 55th day of the study, TUNEL positivity of primary follicles was low among DHEA+VCD group, compared to VCD-treated group. Meanwhile, at the time points of day 35th and 55th days, the follicles began to exhibit various stages of cystogenesis up to the complete transformation into a follicular cyst together with follicular atresia, often referred as a state of DHEA-polycystic ovary rat model [24,25]. Therefore, dosage and duration of use should be taken into account in implementing DHEA treatment in rat models. Thompson et al. [26] studied repeated dose of VCD on female F344 rats for 15 days with a coinjection of E2 (0.1mg/kg) and concluded that this co-injection protocol selectively protected primary follicles from VCD-induced follicular loss. Same authors also used an estrogen receptor agonist (genistein) in the same setting and found that its concurrent treatment with genistein and VCD restored caspase-3 activity to control levels. Current study together with those of Thompson et al. [26] and Elbetagy et al. [23] emphasizes that hormonal modification of ovarian milieu may be protective against apoptosis.

In summary, our work has clearly shown that over a short and long term, DHEA affords protection against VCD-induced ovariotoxicity by increasing the numbers of small preantral follicles and decreasing apoptotic cells in a rat model of ovariotoxicity. Extrapolating these results to human tissues needs to be well elucidated. However, long-term administration of DHEA alone may increase atresia. When used with VCD, an increase in normal primordial follicles was thought to be due to a condition affecting the mechanism of apoptosis in the ovarian microenvironment. Further work is needed to explain its mechanism.

#### Scientific Responsibility Statement

The authors declare that they are responsible for the article's scientific content including study design, data collection, analysis and interpretation, writing, some of the main line, or all of the preparation and scientific review of the contents and approval of the final version of the article.

#### Animal and human rights statement

All procedures performed in this study were in accordance with the ethical standards of the institutional and/or national research committee and with the 1964 Helsinki declaration and its later amendments or comparable ethical standards. No animal or human studies were carried out by the authors for this article.

Funding: This project was supported by Eskişehir Osmangazi University scientific committee with the number of 200811013.

#### Conflict of interest

None of the authors received any type of financial support that could be considered potential conflict of interest regarding the manuscript or its submission.

#### References

- Burfer HG. Androgen production in women. *Fertil Steril*. 2002 ;77 (Suppl. 4):S3-S5.
- Mamas L, Mamas E. Premature ovarian failure and dehydroepiandrosterone. *Fertil Steril*. 2009; 91:644-6.
- Casson PR, Lindsay MS, Pisarska MD, Carson SA, Buster JE. Dehydroepiandrosterone supplementation augments ovarian stimulation in poor responders: a case studies. *Hum Reprod*. 2000; 15:2129-32
- Barad D, Brill H, Gleicher N. Update on the use of dehydroepiandrosterone supplementation among women with diminished ovarian function. *J Assist Reprod Genet*. 2007;24:629-34.
- Barad D, Gleicher N. Effect of dehydroepiandrosterone on oocyte and embryo yields, embryo grade and cell number in IVF. *Hum Reprod*. 2006;21:2845-49.
- Sonmezer M, Cil AP, Oktay K. Ongoing pregnancies from early retrieval of prematurely developing antral follicles after DHEA supplementation. *Reprod Biomed Online*. 2009;19:816-9.
- Sonmezer M, Ozmen B, Cil AP, Ozkavukcu S, Tasi T, Olmus H, et al. Dehydroepiandrosterone supplementation improves ovarian response and cycle outcome in poor responders. *Reprod Biomed Online* 2009;19:508-13.
- Gleicher N, Ryan E, Weghofer A, Blanco-Mejia S, Barad DH. Miscarriage rates after dehydroepiandrosterone (DHEA) supplementation in women with diminished ovarian reserve: a case control study. *Reprod Biol Endocrinol*. 2009;7:108.
- Casson PR, Santoro N, Elkind-Hirsch K, Carson SA, Hornsby PJ, Abraham G, et al. Postmenopausal dehydroepiandrosterone administration increases free insulin-like growth factor-I and decreases high-density lipoprotein. A six month trial. *Fertil Steril*. 1998;70:107-10.
- Yan Z, Lee GY, Anderson E. Influence of dehydroepiandrosterone on the expression of insulin-like growth factor-1 during cystogenesis in polycystic rat ovaries and in cultured rat granulosa cells. *Biol Reprod*. 1997;57:1509-16.
- Hassa H, Aydin Y, Ozatik O, Erol K, Ozatik Y. Effects of dehydroepiandrosterone (DHEA) on follicular dynamics in a diminished ovarian reserve in vivo model. *Syst Biol Reprod Med*. 2015; 61(3): 117-21.
- Sahambi KS, Visser JA, Themmen APN, Mayer LP, Devine PJ. Correlation of serum anti-Mullerian hormone with accelerated follicle loss following 4-vinylcyclohexene diepoxide-induced follicle loss in mice. *Reprod Toxicol*. 2008;26:116-22.
- Hu X, Christian PJ, Thompson KE, Sipes IG, Hoyer PB. Apoptosis induced in rats by 4- vinylcyclohexene diepoxide is associated with activation of caspase cascades. *Biol Reprod*. 2001;65:87-93.
- Romero-Aleshire MJ, Diamond-Tanic MK, Hasty AH, Hoyer PB, Brooks HL. Loss of ovarian function in the VCD Mouse-model of menopause leads to insulin resistance and a rapid progression into metabolic syndrome. *Am J Physiol Regul Integr Comp Physiol*. 2009; 297:587-92. DOI:10.1152/ajpregu.90762.2008
- Keating AF, J Mark C, Sen N, Sipes IG, Hoyer PB. Effect of phosphatidylinositol-3 kinase inhibition on ovotoxicity caused by 4-vinylcyclohexene diepoxide and 7,12-dimethylbenz[a]anthracene in neonatal rat ovaries. *Toxicol Appl Pharmacol*. 2009; 241:127-34.
- Lin SY, Cui H, Yusta B, Belsham DD. IGF-I signaling prevents dehydroepiandrosterone (DHEA)-induced apoptosis in hypothalamic neurons. *Mol Cell Endocrinol*. 2004; 214(1-2): 127-35.
- Charalampopoulos I, Alexaki VI, Tsatsanis C, Minas V, Dermizaki E, Lasaridis I, et al. Neurosteroids as endogenous inhibitors of neuronal cell apoptosis in aging. *Ann N Y Acad Sci*. 2006;1088:139-52.
- Mayer LP, Pearsall NA, Christian PJ, Devine PJ, Payne CM, McCuskey MK, et al. Long-term effects of ovarian follicular depletion in rats by 4-vinylcyclohexene diepoxide. *Reprod Toxicol*. 2002;16: 775-81.
- Flaws JA, Doerr JK, Sipes IG, Hoyer PB. Destruction of preantral follicles in adult rats by 4-vinyl-1-cyclohexene diepoxide. *Reprod Toxicol*. 1994;8:509-14
- Springer LN, Flaws JA, Sipes IG, Hoyer PB. Follicular mechanisms associated with 4-vinylcyclohexene diepoxide-induced ovotoxicity in rats. *Reprod Toxicol*. 1996;10: 137-43.
- Rajah R, Glaser EM, Hirshfield AN. The changing architecture of the neonatal rat ovary during histogenesis. *Dev Dyn*. 1992; 194(3):177-92.
- Bukovsky A, Gupta SK, Virant-Klun I, Upadhyaya NB, Copas P, Van Meter SE, et al. Study origin of germ cells and formation of new primary follicles in adult human and rat ovaries. *Methods Mol Biol*. 2008;450:233-65.
- ElBeltagy K, Honda K, Ozaki K, Misugi T, Tokuyama O, Kimura M, et al. In vitro effect of dehydroepiandrosterone sulfate on steroid receptors, aromatase, cyclooxygenase-2 expression, and steroid hormone production in preovulatory human granulosa cells. *Fertil Steril*; 2007; 88( Suppl.4):1135-42.
- Ward R, Costoff A, Mahesh VB. The induction of polycystic ovaries in mature cycling rats by the administration of dehydroepiandrosterone (DHA). *Biol Reprod*. 1987; 18: 614-23.
- Knudsen JF, Mahesh VB. Dehydroepiandrosterone induced polycystic ovaries and acyclicity in rats. *Fertil Steril*. 1975; 26: 807-17.
- Thompson KE, Sipes IG, Greenstein BD, Hoyer PB. 17β-estradiol affords protection against 4- vinylcyclohexene diepoxide-induced ovarian follicle loss in Fischer-344 rats. *Endocrinology*. 2002;143:1058-65.

#### How to cite this article:

Özer MC, Kaya M, Turp AB, Bal C, Erkasap N, Coşan DT, Hassa H. Effect of dehydroepiandrosterone on ovarian morphology and follicular apoptosis following 4-vinylcyclohexene diepoxide induced premature follicle loss in rats. *Ann Clin Anal Med* 2020;11(2):104-109